



Delayed Toxicity of a Patient with Valproic Acid Overdose

You-Ming Chen¹, Chien-Chin Hsu², Kuo-Tai Chen³

¹Department of Emergency, Chi-Mei Medical Center, Tainan, Taiwan, Province of China

²Department of Biotechnology, Southern Tainan University of Technology, Tainan, Taiwan, Province of China

³Department of Emergency Medicine, Taipei Medical University School of Medicine, Taipei, Taiwan, Province of China

Cite this article as: Cheng YM, Hsu CC, Chen KT. Delayed Toxicity of a Patient With Valproic Acid Overdose. J Emerg Med Case Rep 2018; 9: 23-5.

ABSTRACT

Introduction: Nowadays, Valproic acid (VPA) is widely used for the treatment of seizures, mood disorder, schizophrenia, and migraine prophylaxis. With its extended use, the incidence of acute VPA poisoning is increasing. Though most patients with VPA overdose may recover with supportive care, delayed toxicity may result in the underestimation of the severity.

Case Report: We reported on a case of VPA and benzodiazepine overdoses with two-phase alternations of mental states, and the peak serum VPA level developed 22 h post-ingestion. The patient underwent an emergency tracheal intubation and artificial ventilation for the presence of acute respiratory failure and coma. After two courses of hemodialysis, he recovered to clear consciousness and spontaneous respiration.

Conclusion: Toxidromes of VPA poisoning can develop late after acute poisoning. Accordingly, we suggest that all intoxicated patients should undergo prolonged observation until the serum VPA level has decreased and the toxidromes have disappeared. Activated charcoal, carnitine, naloxone, and hemodialysis/hemoperfusion are potential regimens to decrease absorption, to reverse the toxidromes, and to enhance elimination for patients with VPA poisoning.

Keywords: Valproic acid, hemodialysis, delayed toxicity, overdose

Received: 19.06.2017 **Accepted:** 11.09.2017

Introduction

Valproic acid (VPA) is widely used for the treatment of complex partial seizures and simple and complex absence seizures. In recent years, the extended use of this drug has included mood disorders, schizophrenia, bipolar disorder, personality disorder, and migraine prophylaxis (1). Accordingly, the incidence of acute VPA poisoning, resulting from intentional or accidental overdose, is increasing (2). Acute VPA poisoning incurs various toxicities in different systems, including central nervous system depression, respiratory depression, metabolic acidosis, hyperammonemia, hypoglycemia, hypophosphatemia, hypocalcemia, hypernatremia, hepatotoxicity, pancreatitis, hypotension, seizure, and bone marrow suppression (1). Some VPA is marketed in enteric-coated and extended-release tablets, which prolongs the time from ingestion to reach the peak plasma concentrations. Furthermore, a large amount of pills and co-ingestion of other drugs might also delay gastric emptying and reduce bioavailability early after ingestion (3, 4). Most emergency physicians are not familiar with these toxidromes and the clinical courses of patients with VPA poisoning.

We report on a case of VPA and benzodiazepine overdose with two-phase alternations of mental states and the peak serum VPA level that developed 22 h post-ingestion. We review the literature and hope to discover recommended measures for

Address for Correspondence:

Kuo-Tai Chen, School of Medicine, College of Medicine, Taipei Medical University, Department of Emergency Medicine, Taipei, Taiwan, Province of China
E-mail: 890502@mail.chimei.org.tw

©Copyright 2018 by Emergency Physicians Association of Turkey - Available online at www.jemcr.org

decontamination, in-hospital management, clinical manifestations, and possible courses for patients with VPA poisoning.

Case report

A 26-year-old man with a history of mood disorder was treated in a clinic for 5 y. His family found him attempting to commit suicide by ingesting a large amount of pills [including Trazodone (50 mg): 25 pills; Sodium Valproate (500 mg) (extended-release preparation): 50 pills; Estazolam (2 mg): 50 pills; and Fludiazepam (0.25 mg): 25 pills]. On arrival, his vital signs were as follows: body temperature, 35.6°C; pulse, 79 beats/min; respiratory rate, 19/min; and arterial pressure, 103/65 mmHg. A physical examination revealed a comatose man with flaccid extremities and symmetrical, normal-response pupils. Laboratory investigations demonstrated a white blood cell count of 7500 counts/ μ L, a platelet count of 283000 counts/ μ L, 15.2 g/dL hemoglobin, 92 g/L glucose, 0.9 g/L creatinine, 139.6 mEq/L sodium, 3.32 mEq/L potassium, 19 IU/L aspartate transaminase, 25 IU/L alanine transaminase, and 12.8 mg/L VPA levels. A plain radiograph of the patient's chest was normal, and his electrocardiogram showed sinus rhythm.

After 10 h of supportive care, the patient improved to clear consciousness despite the followed-up VPA serum level increasing to 82.2 mg/L. Nevertheless, his consciousness deteriorated gradually and was accompanied by the development of dyspnea. Overall, 22 h after his suicide attempt, the VPA level further increased to 432.3 mg/L, and hyperammonemia (ammonia, 49 mol/L) was discovered. He underwent emergency tracheal intubation and artificial ventilation for the presence of acute respiratory failure and coma. To facilitate the elimination of his accumulated serum VPA, we arranged two courses of hemodialysis in 12 h. One episode of tonic-clonic seizure attack occurred during the first course of hemodialysis, and the seizure subsided without the application of an anticonvulsant agent. The patient recovered to clear consciousness after hemodialysis and the VPA level decreased to 115.1 mg/L (Figure 1). He was extubated 3 days later and was discharged after 3 days of support care without permanent sequelae.

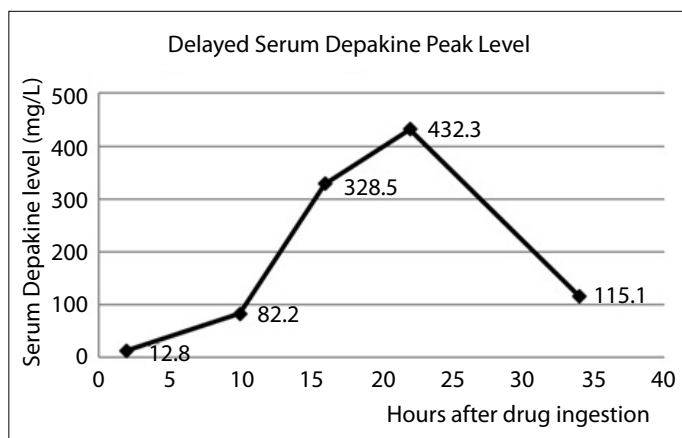


FIGURE 1. Serial serum levels of valproic acid. The peak level appeared 22 hours post-ingestion and the serum levels decreased after two courses of hemodialysis.

Discussion

According to the Toxic Exposure Surveillance System of the American Association of Poison Control Centers, there were 9069 human ingestions of VPA reported to poison centers in the United States in 2004 and 11 of the 13 deaths that ensued involved suicide attempts (2). In most severe intoxicated cases, the patients ingested more than one substance, and this influenced the timing and severity of clinical presentations in the emergency department (4, 5).

In our presented case, the patient took large amounts of benzodiazepine, selective serotonin reuptake inhibitors, and extended-release VPA. The first two kinds of drugs resulted in the early phase of coma and the patient's symptoms were resolved with supportive care only. This gave the emergency physicians and the patient's family a false sense of security. The VPA level reached the peak 22 h post-ingestion and resulted in the delayed phase of central nervous system depression. Treatment guidelines from the American Association of Poison Control Centers state that the peak plasma concentration would be achieved 4–17 h following the ingestion of extended-release VPA, and the gastrointestinal tract absorption of VPA might be further impeded by coingestants and simultaneously, by large amounts of pills (5). Ingels et al. reported 173 cases of VPA intoxication and 15% of the reported cases showed delayed toxicity (4). These patients and this case reminded the physicians that the toxidromes of VPA poisoning can develop late, and, therefore, the involved patients should undergo prolonged observation until the serum VPA level has decreased and the toxidromes have disappeared.

VPA is metabolized mainly by the liver via glucuronic acid conjugation and CYP450 beta- and omega-oxidation. After acute overdose, metabolites rather than the drug itself are responsible for the toxicity of VPA (1, 5, 6). There is no effective antidote for VPA poisoning, and, therefore, supportive care constituted the mainstay of the treatment. Once emergency physicians encounter a suspected VPA poisoning case, activated charcoal can be given to minimize gastrointestinal tract absorption within 2 h post-ingestion. Extensive tests for metabolic and hematologic abnormalities and serial serum VPA levels are necessary. L-carnitine can reduce the formation of toxic metabolites and provide potential benefit in the treatment of VPA poisoning (6). However, L-carnitine is an orphan drug and is not available in most facilities. In a few case reports, naloxone successfully reversed the central nervous depression caused by VPA overdose (7). However, naloxone failed to demonstrate similar effects in other cases (8).

In therapeutic concentrations, most VPA is protein-bound and cannot be eliminated by dialysis. However, at higher serum levels, the saturation of the protein-binding site decreases the percentage of protein-bound VPA, which makes extracorporeal elimination a practical option (9, 10). Our case report and a number of others have shown that hemodialysis and hemoperfusion shorten the serum half-lives of VPA and effectively reverse patients' hemodynamic instability and central nervous depression (8-11).

Conclusion

Intentional VPA overdose is a potentially lethal medical emergency and VPA toxicity may be delayed. Prolonged close monitoring and supportive care are sufficient for most intoxicated cases. Activated charcoal, L-carnitine, naloxone, and hemodialysis/hemoperfusion are potential regimens to decrease absorption, reverse toxidromes, and enhance elimination for patients with VPA poisoning.

Informed Consent: Written informed consent couldn't be obtained due to the impossibility of reaching the patient.

Peer-review: Externally peer-reviewed.

Author Contributions: Concept - Y.M.C., K.T.C.; Design - C.C.H.; Supervision -K.T.C.; Resources - Y.M.C.; Materials - Y.M.C.; Data Collection and/or Processing -C.C.H., K.T.C.; Analysis and/or Interpretation - C.C.H.; Literature Search - C.C.H., K.T.C.; Writing Manuscript - C.C.H., K.T.C.; Critical Review - C.C.H.

Conflict of Interest: No conflict of interest was declared by the authors.

Financial Disclosure: The authors declared that this study has received no financial support.

References

1. Sztajnkrzyer MD. Valproic acid toxicity: overview and management. *J Toxicol Clin Toxicol*. 2002; 40: 789–801. [\[CrossRef\]](#)
2. Watson WA, Litovitz TL, Rodgers GC, et al. 2004 Annual Report of the American Association of Poison Control Centers Toxic Exposure Surveillance System. *Am J Emerg Med*. 2005; 23:589–666. [\[CrossRef\]](#)
3. Payen C, Frantz P, Martin O, et al. Delayed toxicity following acute ingestion of valpromide. *Hum Exp Toxicol*. 2004; 23: 145–8. [\[CrossRef\]](#)
4. Ingels M, Beauchamp J, Clark RF, et al. Delayed valproic acid toxicity: a retrospective case series. *Ann Emerg Med*. 2002; 39: 616–621. [\[CrossRef\]](#)
5. Manoguerra AS, Erdman AR, Woolf AD, et al. American Association of Poison Control Centers. Valproic acid poisoning: an evidence-based consensus guideline for out-of-hospital management. *Clin Toxicol (Phila)*. 2008; 46: 661–76. [\[CrossRef\]](#)
6. Lheureux PE, Hantson P. Carnitine in the treatment of valproic acid-induced toxicity. *Clin Toxicol (Phila)*. 2009; 47: 101–11. [\[CrossRef\]](#)
7. Steiman GS, Woerpel RW, Sherard ES Jr. Treatment of accidental sodium valproate overdose with an opiate antagonist. *Ann Neurol*. 1979; 6: 274. [\[CrossRef\]](#)
8. Mortensen PB, Hansen HE, Pedersen B, et al. Acute valproate intoxication: biochemical investigation and hemodialysis treatment. *Int J Clin Pharmacol Ther Toxicol*. 1983; 21: 64–8.
9. Ghannoum M, Laliberté M, Nolin TD, et al. Extracorporeal treatment for valproic acid poisoning: systematic review and recommendations from the EXTRIP workgroup. *Clin Toxicol (Phila)*. 2015; 53: 454–65 [\[CrossRef\]](#)
10. Hicks LK, McFarlane PA. Valproic acid overdose and haemodialysis. *Nephrol Dial Transplant*. 2001; 16: 1483–6. [\[CrossRef\]](#)